

Arthroscopic Transfer of the Long Head of the Biceps Tendon: Functional Outcome and Clinical Results

Mark C. Drakos, M.D., Nikhil N. Verma, M.D., Lawrence V. Gulotta, M.D.,
Frank Potucek, B.A., Samuel Taylor, B.A., Stephen Fealy, M.D.,
Ronald M. Selby, M.D., and Stephen J. O'Brien, M.D.

Purpose: We sought to evaluate clinical and functional outcome in a cohort of patients who underwent transfer of the long head of the biceps tendon (LHBT). **Methods:** Patients who were diagnosed with biceps pathology or instability underwent an arthroscopic assisted or all arthroscopic transfer LHBT as either an isolated procedure or part of another shoulder procedure by the senior author. The procedure was performed using a new arthroscopic subdeltoid technique. Forty shoulders in 39 patients were examined at a minimum of 2 years. Patients underwent complete shoulder evaluation and clinical outcomes were scored based on American Society of Shoulder and Elbow Surgeons (ASES), University of California at Los Angeles (UCLA), and L'Insalata questionnaires. Ipsilateral and contralateral metrics were also evaluated. **Results:** Forty shoulders (13 female, 26 male, 1 bilateral; average age, 38.5 years) were evaluated with L'Insalata, UCLA, and ASES questionnaires, scoring 75.57, 27.32, and 78.72, respectively. In the 25 patients who had an isolated LHBT transfer, the L'Insalata, UCLA, and ASES scores were 85.2, 29.5, and 84.8, respectively. Three patients had early traumatic failure related to noncompliance with postoperative rehabilitation protocol. This included the only 2 patients who had a Popeye sign at follow-up during active elbow flexion. There was not a statistically significant side-to-side strength difference using a 10-pound weight. Eighty percent of patients were self-rated as good to excellent, and 20% of patients were self-graded as fair or poor, which includes the 3 failures mentioned above. All of the patients reported no arm pain at rest with regard to the biceps. Ninety-five percent of patients reported no biceps tenderness upon palpation of the bicipital groove. Five patients complained of fatigue discomfort (soreness) isolated to the biceps muscle following resisted elbow flexion. **Conclusions:** Arthroscopic subdeltoid transfer of the LHBT is an appropriate and reliable intervention for active patients with chronic, refractory biceps pathology. There was no loss of strength for biceps curls. All patients reported no pain isolated to biceps muscle at rest. Ninety-five percent of patients had resolution of their preoperative biceps symptoms. **Level of Evidence:** Level IV, therapeutic case series. **Key Words:** Biceps pathology—Biceps transfer—Subdeltoid arthroscopy.

Inflammation of the long head of the biceps (LHB) brachii tendon is a well-recognized source of shoulder pain. A recent study by Alpantaki et al.¹ used immunohistochemical stains to identify sympathetic

and sensory neural elements in the tendon of the LHB. Their findings demonstrated that the tendon of the LHB is innervated by a network of nerve fibers which may play a role in the etiology of shoulder pain. However, the

From the Sports Medicine and Shoulder Service, Hospital for Special Surgery (M.C.D., L.V.G., F.P., S.T., S.F., S.J.O.), Cornell Medical Center, New York, New York, and the Departments of Orthopedics at Rush University Medical Center (N.N.V.), Chicago, Illinois, and St. Vincent's Hospital, New York Medical College (R.M.S.), New York, New York, U.S.A.

Address correspondence to Mark C. Drakos, M.D., The Hospital for Special Surgery, Department of Sports Medicine, 535 East 70th St., New York, NY 10021, U.S.A. E-mail: drakosm@hss.edu

© 2008 by the Arthroscopy Association of North America

0749-8063/08/2402-6154\$34.00/0

doi:10.1016/j.arthro.2007.07.030

diagnosis and management of biceps tendonitis remains controversial. Biceps tendon pathology can occur in isolation or in conjunction with other shoulder injuries, further complicating both diagnosis and treatment. Initial management should consist of nonoperative treatments, such as activity modification, physical therapy, oral anti-inflammatories, and local steroid injections.²

When nonoperative management fails, surgical options include tenotomy or tenodesis. Tenotomy has been reported to provide reliable pain relief (95% to 100%), but complications including cosmetic deformity and fatigue discomfort are common in younger, more active patients.³⁻⁶ Tenodesis techniques have traditionally involved bony fixation of the tendon to the proximal humerus. Multiple techniques of fixation have been described, including bone tunnels, suture anchors, staples, interference screws, and soft tissue tenodesis to the transverse ligament. While most studies report satisfactory pain relief, some reports have indicated a high failure rate (6% to 40%) of the tenodesis.^{5,7-14}

Recently, an arthroscopic technique of transferring the LHB tendon to the conjoint tendon has been described.¹⁵ This is an attractive option because it allows for soft tissue healing which may result in less pain than soft tissue to bone healing. Also, the transfer allows the surgeon to directly visualize the tension being applied to the tendon during suturing to prevent overtightening. While reports comparing tenotomy to tenodesis have shown little clinical difference between techniques, there have been no reports comparing tenodesis with transfer of the biceps tendon.¹⁶

In specific cases where the physical exam is consistent with biceps pain and a diagnosis of biceps tendonitis has been attained, it is our belief that transfer of the LHB may yield relief of pain and symptoms. In addition, this procedure offers advantages over biceps tenodesis and tenotomy. Biceps pain can be an isolated pathology or part of a larger disease process such as impingement syndrome. However, biceps symptoms can be isolated from other causes of shoulder pain, and treatments may be examined. This study sought to evaluate the clinical function of the biceps in a cohort of patients who underwent transfer of the LHB with a minimum of 2 years of follow-up. We hypothesize that transfer of the LHB is an appropriate procedure which will give patients predictable pain relief. Furthermore, those undergoing transfer will experience equivalent or improved pain relief with less morbidity when compared against the historical controls of tenodesis or tenotomy.

METHODS

Fifty-three patients diagnosed with either biceps tendonitis or instability of the LHB tendon (LHBT) who were initially unsuccessfully treated with conservative therapy underwent an arthroscopic assisted or all arthroscopic transfer of the LHBT to the conjoint tendon (Fig 1). One patient was treated bilaterally; his shoulders were considered independently. All subdeltoid biceps transfers were performed by the senior author (S.J.O.) over a 3-year period between 2001 and 2004. Intraoperatively, 15 shoulders had a positive arthroscopic active compression test and evidence of intra-articular subluxation.¹⁷ Ten shoulders had evidence of bicipital fraying, and 2 shoulders had bicipital tenosynovitis. Patients who underwent concomitant procedures for instability, full- or partial-thickness rotator cuff tears, degenerative joint disease, labral tears, or acromion abnormalities were not excluded from this study (Table 1).

Thirty-nine patients (40 procedures) were available for clinical follow-up at a mean of 28 months postoperatively (range, 24 to 53 months). Nine patients were unable to be located and 4 patients declined to be involved in the study. Two patients were treated with arthroscopic assisted biceps transfer, and the remaining patients received all arthroscopic LHBT transfer procedures. Twenty-five of the 40 procedures were isolated transfers of the LHBT to the conjoint tendon. The study included 26 men and 13 women with a mean age of 38.5 years at the time of surgery (range, 15 to 67 years). This procedure was specifically designed for a young, active population with biceps tendon pathology.

Biceps tendonitis was diagnosed by the following algorithm: each patient reported a clinical history of pain in the anterior shoulder which was reproduced by tenderness on palpation of the intertubercular groove during physical examination. These findings were frequently accompanied by a positive active compression test.¹⁸ Twenty of the 40 shoulders (50%) had a positive active compression test on initial exam by demonstrating deep pain on resisted flexion in internal rotation and relief of the pain on resisted flexion in external rotation. It is essential that the physical examination findings are correlated with the patient's history of symptoms.

At follow-up, the patients were evaluated clinically using the L'Insalata Shoulder Rating Questionnaire (100-point system), a physical examination that was scored using the American Shoulder and Elbow Surgeons (ASES) evaluation form (100-point system), and the University of California at Los Angeles

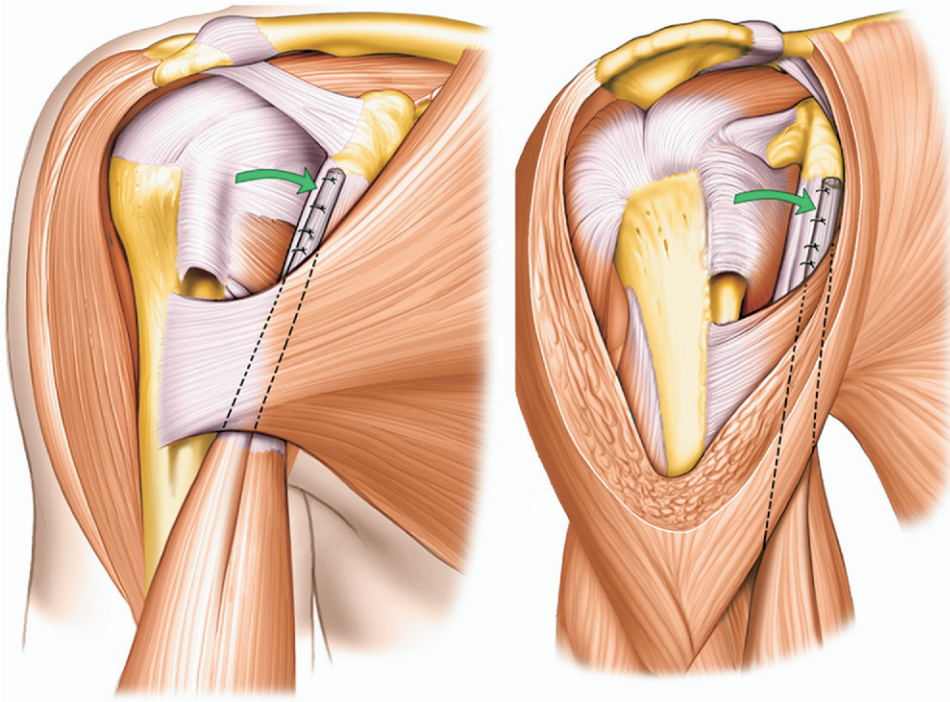


FIGURE 1. Graphic depiction of an anteroposterior and lateral view of a completed transfer of the long head of the biceps tendon to the anterior aspect of the lateral edge of the conjoint tendon.

(UCLA) shoulder evaluation test (35-point system). Patients also used a visual pain scale (0 to 10) and were asked to rate their overall satisfaction with the procedure at the time of follow-up. Patients were requested to complete a thorough physical examination of the upper extremity at our institution, performed by a coinvestigator other than the operating surgeon. The questionnaires were also scored by a coinvestigator other than the operating surgeon. In addition to an evaluation of both ipsilateral and contralateral metrics, patients were asked to perform isolated biceps curls with a 10-pound weight until fatigue

with both the affected and the contralateral arms. Patients were asked about postoperative symptoms of fatigue and discomfort. Patients were also evaluated for a Popeye sign (PS; elbow flexed with the arm at the patient's side).

Once completed, the L'Insalata questionnaire was scored according to the weighted system described.¹⁹ Similarly, once the physical examination was completed, the ASES questionnaire and the UCLA shoulder examination were scored.²⁰ The SPSS software system (SPSS Inc., Chicago, IL) was used to analyze the data using the Student *t* test and χ^2 methods.

Surgical Technique

The procedure was described in 2005 by Verma et al.¹⁵ It is performed with the patient in the beach chair position. An examination under anesthesia is done to assess instability. A diagnostic shoulder arthroscopy is performed using the standard posterior portal for visualization and a superolateral portal for working.²¹ The biceps anchor can be visualized when the arthroscope is placed through the superolateral portal. The biceps is then tagged with 2 to 3 polydioxanone sutures. Tenotomy is performed arthroscopically by a simple resection as close as possible to the

TABLE 1. Breakdown of Concomitant Surgical Procedures

Operative Procedures	No.
Isolated LHBT transfer	25
LHBT transfer and acromioplasty (5 with acromioclavicular joint resection)	9
LHBT transfer and rotator cuff repair	3
LHBT transfer and labral repair	1
LHBT transfer and instability repair	1
LHBT transfer and total shoulder	1

Abbreviation: LHBT, long head of the biceps tendon.

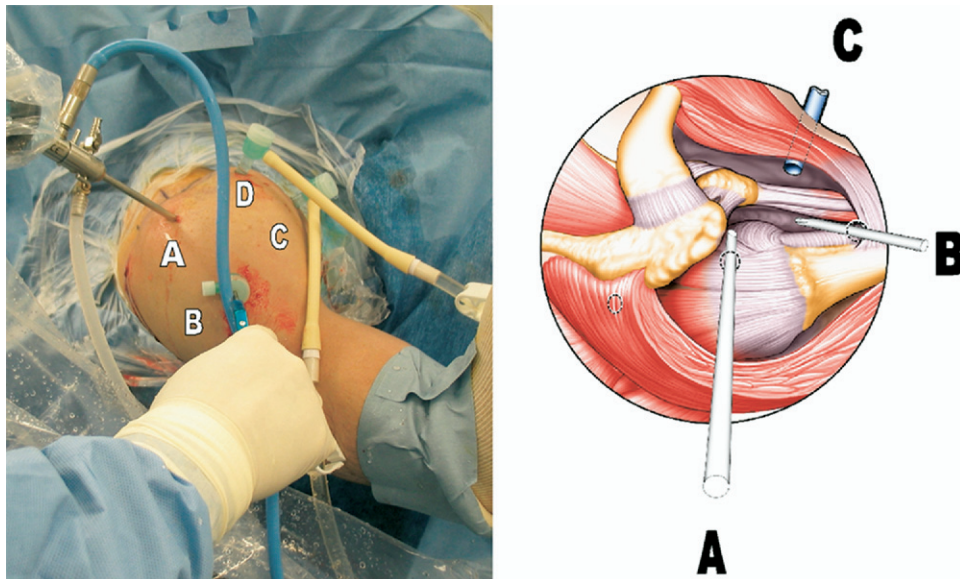


FIGURE 2. Subdeltoid arthroscopy set-up and portal placement. (A) Anterolateral portal used for viewing while working in the subdeltoid space. (B) Pectoralis portal used for working. (C) Conjoint portal used for suture tying during transfer. (D) Anterior, accessory portal used for inflow. Note in the set-up on the left there are 2 inflows to allow greater insufflation of the space. On the right there is only 1 inflow through the coracoid portal.

biceps origin on the superior labrum. An acromioplasty extending from the anterolateral border of the acromion to the acromioclavicular joint is then performed to allow exposure of the conjoint tendon medially. The subdeltoid space is further exposed distal to the pectoralis major tendon. Next a spinal needle is used to localize placement of a superior, anterolateral portal as well as an inferior portal at the junction of the LHBT and pectoralis tendons. These portals facilitate adequate visualization of the subdeltoid space and allow for the retrieval of the LHB and suturing of the long head to the conjoint tendon (Figs 2-4). The biceps tendon is sutured to the anterolateral aspect of the conjoint tendon to avoid coracoid impingement and injury to the musculocutaneous nerve, which has been visualized in approximately 5% of cases. In our experience, the integrity of the conjoint tendon has always permitted appropriate suture tension.

RESULTS

Forty shoulders were evaluated at an average of 28 months postoperatively (range, 24 to 53 months). L'Insalata, UCLA, and ASES scores were 78.9, 27.8, and 79.6, respectively. Ranges were 35.7 to 100 (L'Insalata), 12 to 35 (UCLA), and 30 to 100 (ASES). Five percent of patients had a PS at rest or during active elbow flexion. This was defined as any abnor-

mal shortening or defect of the biceps muscle when the examiner compared it to the contralateral, nonaffected side. Both of these patients had a failure of the biceps transfer and elected not to have a repeat pro-

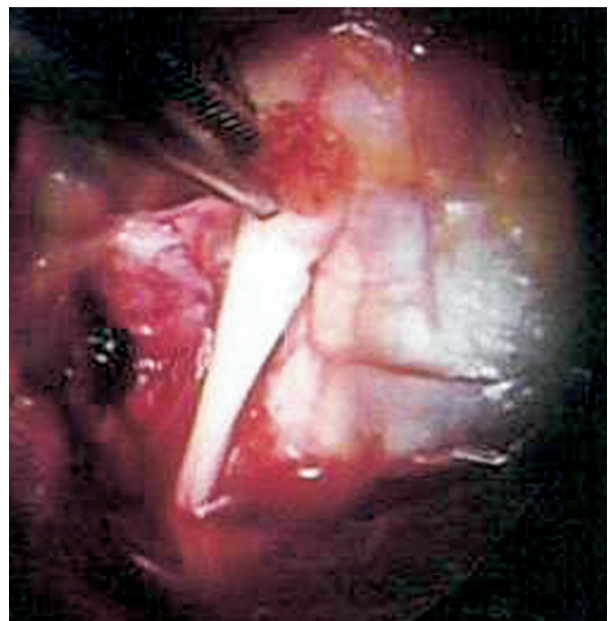


FIGURE 3. Tensioning and alignment of the tagged long head of the biceps tendon on the left with the conjoint tendon on the right.

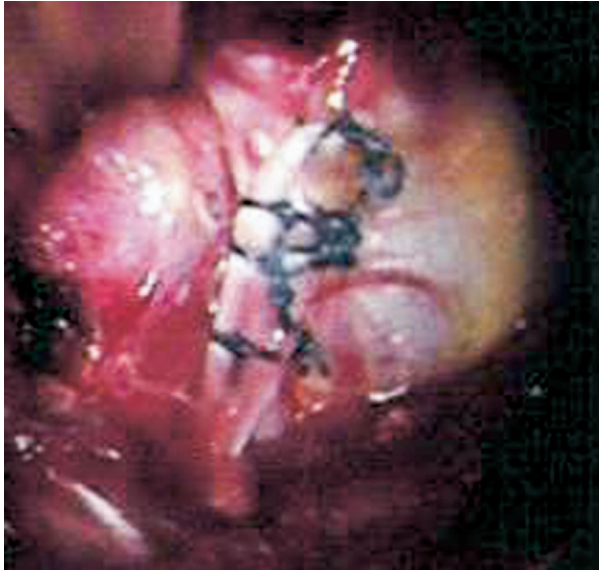


FIGURE 4. Completed transfer of the long head of the biceps tendon to the conjoint tendon.

cedure. Each patient also reported their subjective satisfaction as poor. Five of the 40 patients (12.5%) complained of fatigue discomfort (soreness) isolated to the biceps muscle following resisted elbow flexion. Weight testing with the injured arm yielded an average of 33.2 repetitions of 10-pound curls (range, 0 to 50). Testing of the contralateral, noninjured arm yielded an average of 34.5 repetitions of 10-pound curls (range, 0 to 50). Side-to-side strength difference was 1.72 repetitions with the 10-pound weight. This difference was not statistically significant. There was also no statistically significant difference in side-to-side strength difference between age groups or based on sex. All of the patients reported relief of arm pain at rest distally and proximally. Ninety-five percent of patients (38/40) reported relief of biceps tenderness upon palpation of the bicipital groove.

In the 25 patients who had an isolated LHBT transfer, the L'Insalata, UCLA, and ASES scores were

85.2, 29.5, and 84.8, respectively. This group showed a trend toward better clinical outcome than the cohort of patients who had concomitant shoulder procedures in addition to an LHBT transfer ($P < .09$; Table 2). Because of the small cohort size, we were unable to demonstrate statistical significance. There were no significant differences between the ipsilateral and contralateral sides with regards to strength metrics in the isolated group. There were no patients with a PS. Only 2 patients (5%) had fatigue discomfort symptoms. Twenty-three patients (92%) reported good, very good, or excellent results.

Eighty percent of all shoulders (32/40) were subjectively rated as good, very good, or excellent. Twenty percent of patients were self-rated as fair ($N = 6$) or poor ($N = 2$). Both patients with a poor result and 1 patient with a fair result had postoperative reruptures of their transferred biceps tendon within the first 6 weeks because of a failure to comply with postoperative protocols. Furthermore, all 3 of these patients had concomitant pathologies which required additional procedures at the time of surgery (2 rotator cuff repairs and 1 acromioplasty). In the cohort of patients whose transfer survived the first 6 weeks postoperatively, there were only 2 patients with complaints of fatigue discomfort and no patients had a PS. One patient had postoperative breast asymmetry which resolved after 3 months. Another patient who was a softball pitcher had persistent pain in the late cocking phase of throwing and ultimately required a repeat arthroscopy to remove scar tissue. At the time of follow-up, the transfer was found to be completely healed.

DISCUSSION

The pathogenesis of the painful shoulder may involve lesions within the LHBT along its course in the bicipital groove or at its insertion on the labrum. Eakin et al.²² classified LHBT pathology into 3 categories: 1) biceps tendon degeneration (tendonitis); 2) origin disorders (SLAP lesions); and 3) tendon instability.

TABLE 2. Comparison of Isolated and Combined Procedures

Group	N	Popeye Sign (%)	Fatigue Discomfort (%)	L'Insalata	ASES	UCLA	Str. Diff.	Satisfaction
LHBT plus concomitant procedures	15	2 (13.3)	3 (20)	72.5	74.1	25.6	1.7	3.13
Isolated LHBT transfer	25	0 (0)	2 (8)	85.2	84.8	29.5	1.9	3.8
Total	40	2 (5)	5 (12)	78.9	79.6	27.8	1.8	3.5

Abbreviations: ASES, American Society of Shoulder and Elbow Surgeons; LHBT, long head of biceps tendon; str. diff., strength difference; UCLA, University of California at Los Angeles.

Frequently, biceps tendonitis may be a secondary phenomenon caused by impingement. Decreased space in the coracoacromial arch may lead to biceps irritation and mechanical symptoms.^{2,11} Other associated pathologies included rotator cuff tears, labral lesions, and acromioclavicular joint arthritis. This often complicates the clinical picture.^{8,14,23-27}

Once accurately diagnosed, the initial treatment of biceps tendonitis is conservative. Measures such as physical therapy, anti-inflammatories, and injections within the sheath of the biceps tendon are routinely prescribed. However, a subset of patients does exist which is refractory to these modalities. In these patients, operative intervention may be warranted. This is supported by several authors who reported relief of chronic biceps tendonitis symptoms subsequent to the rupture.²⁷⁻²⁹ This has led other groups to advocate tenotomy of the LHBT in specific patient groups.^{6,14,16}

Kelly et al.⁶ reported 40 patients who had arthroscopic release of LHBT. Ninety-six percent of patients were relieved of the tenderness to palpation in the intertubercular groove. However, 70% of patients had a PS and 38% of patients had fatigue discomfort symptoms. The authors advocated tenotomy for individuals over the age of 60 who were not manual laborers. Similarly, Kempf et al.²⁴ advocated LHBT tenotomy in elderly patients with significant biceps pathology. They reported 210 patients with arthroscopically treated rotator cuff tears in which 18% had tenotomy of LHBT. When compared with the non-tenotomized group, the tenotomized group had statistically significant improvements in the level of physical activity, active mobility, and pain parameters. Gill et al.³ demonstrated that arthroscopic biceps tendon release for treatment of bicipital tenosynovitis, dislocation, or partial rupture could yield favorable results. The average ASES score was 81.8. More than 96% of patients did not require any pain medication at follow-

up, and 90% of the patients returned to their previous level of sports.

Historically, tenodesis was the standard operative treatment for these lesions. However, this was most commonly performed with an open technique, and failure rates ranged from 6% to 40%.^{5,7-14} A number of arthroscopic techniques have been described in the past 5 years. However, the majority do not have the appropriate follow-up by which an accurate comparison can be made. Paulos et al.³⁰ compared a wedge tenodesis with a traditional keyhole tenodesis and tenotomy.³⁰ The authors found a 23% incidence of tenderness to palpation of the bicipital groove with a wedge technique and a 6% incidence with the keyhole technique. The authors concluded that functional results of the wedge technique were similar to that of the keyhole technique and with similar pain relief to the tenotomy technique.

In our cohort of biceps transfers, all patients reported relief of arm pain at rest distally and proximally. Ninety-five percent of patients reported relief of biceps tenderness upon palpation of the bicipital groove. There was no statistically significant difference in side-to-side strength differences between the operated and contralateral arms. More than 12% (12.5%) of patients (5/40) complained of fatigue discomfort (soreness) isolated to the biceps muscle following resisted elbow flexion. There were 3 patients (2 poor and 1 fair result) who had a rupture of the biceps transfer repair after the procedure. All 3 patients were noncompliant with the postoperative protocol and were found to have lifted heavy objects in the immediate postoperative period. One of these patients had his LHBT resuspended. The other 2 patients represent the only patients in our group with a PS. This has led us to stress the importance of the adherence to the postoperative protocol, particularly within the first 6 weeks of surgery.

Fifteen of the patients in our study had concomitant diagnoses requiring operative intervention. These procedures may affect the overall result as well as subjective satisfaction. However, it is not uncommon to see biceps tendonitis in addition to other shoulder pathology. In the series by Paulos et al.,³⁰ 78% of patients who underwent operative intervention for biceps pathology had concomitant procedure performed. These were most commonly subacromial decompressions and rotator cuff repairs. While these variables may confound the results, we assert that biceps specific pain when correlated with clinical exam and radiologic data can be adequately addressed with the transfer procedure.

TABLE 3. *Comparison of Biceps Tenodesis, Tenotomy, and Transfer With Regard to Symptoms*

Symptom	LHBT Tenodesis	LHBT Tenotomy	LHBT Transfer
Fatigue discomfort	0-41%	20-40%	12.5% (5%)
Popeye sign	0-22%	35-70%	5% (0%)
Intertubercular groove pain	6-40%	0-20%	0%

Abbreviation: LHBT, long head of biceps tendon.

Note: Percentages shown in parentheses note the incidence of symptoms in patients without traumatic reruptures in the first 6 weeks postoperatively.

When critically reviewing the operative modalities to treat biceps pathology, the LHBT procedure has clear advantages (Table 3). When compared to tenodesis (unacceptable outcome in 6% to 40% as noted in the literature), there is a lower incidence of anterior shoulder pain.^{2,8-10,12} When compared to tenotomy, the biceps transfer has a lower incidence of a PS and fatigue discomfort symptoms.⁶

While our overall failure rate of the transfer is 7.5%, the patients were relieved of their site-specific biceps symptoms in 95% of cases. The study size is an obvious limitation of the study; however, biceps tendinitis itself is a less common diagnosis, especially in isolation. These factors led the authors to perform a retrospectively designed study. Furthermore, this is a new procedure in which the cohort includes patients who had the surgery performed during the learning curve of the senior author (S.J.O.). Future studies may have improved results as the technique continues to evolve.

CONCLUSIONS

Arthroscopic subdeltoid transfer of the LHBT is a safe and reliable intervention for active patients with chronic, refractory biceps pathology. There was no loss of strength for biceps curls. All patients reported no pain isolated to biceps muscle at rest. Ninety-five percent of patients had resolution of their preoperative biceps symptoms. It appears that this procedure yields equivalent results to tenotomy for pain relief, better results than tenotomy for fatigue discomfort, and equivalent results compared to other methods of tenodesis.

REFERENCES

- Alpantaki K, McLaughlin D, Karagogeos D, Hadjipavlou A, Kontakis G. Sympathetic and sensory neural elements in the tendon of the long head of the biceps. *J Bone Joint Surg Am* 2005;87:1580-1583.
- Neviaser R. Lesions of the biceps and tenonitis of the shoulder. *Orthop Clin North Am* 1980;11:343-348.
- Gill TJ, McIrvin E, Mair SD, Hawkins RJ. Results of biceps tenotomy for treatment of pathology of the long head of the biceps brachii. *J Shoulder Elbow Surg* 2001;10:247-249.
- Huffman G, Wolf E. Results in patients with symptomatic degeneration of the long head of the biceps brachii tendon. *Arthroscopy* 2003;19:5.
- Weber S, Kaufman J. Subpectoral biceps tenodesis in the management of tears of the long head of the biceps: Long term follow-up. *Arthroscopy* 2003;19:6.
- Kelly A, Drakos M, Fealy S, Taylor S, O'Brien S. Arthroscopic release of the long head of the biceps tendon: Functional outcome and clinical results. *Am J Sports Med* 2005;33:208-213.
- Becker DA, Cofield RH. Tenodesis of the long head of the biceps brachii for chronic bicipital tendinitis. Long-term results. *J Bone Joint Surg Am* 1989;71:376-381.
- Dines D, Warren RF, Inglis AE. Surgical treatment of lesions of the long head of the biceps. *Clin Orthop Relat Res* 1982;164:165-171.
- Berlemann U, Bayley I. Tenodesis of the long head of biceps brachii in the painful shoulder: Improving results in the long term. *J Shoulder Elbow Surg* 1995;4:429-435.
- Depalma AF, Callery GE. Bicipital tenosynovitis. *Clin Orthop* 1954;3:69-85.
- Neviaser TJ, Neviaser RJ, Neviaser JS. The four-in-one arthroplasty for the painful arc syndrome. *Clin Orthop Relat Res* 1982;163:107-112.
- O'Donoghue DH. Subluxing biceps tendon in the athlete. *Clin Orthop Relat Res* 1982;164:26-9.
- Post M, Benca P. Primary tendinitis of the long head of the biceps. *Clin Orthop Relat Res* 1989;246:117-125.
- Walch G, Boileau P, Noel E, Liotard JP, Dejour H. [Surgical treatment of painful shoulders caused by lesions of the rotator cuff and biceps, treatment as a function of lesions. Reflections on the Neer's concept]. *Rev Rhum Mal Osteoartic* 1991;58:247-257.
- Verma N, Drakos M, O'Brien S. Arthroscopic transfer of the long head of the biceps to the conjoint tendon. *Arthroscopy* 2005;21:764.
- Osbahr DC, Diamond AB, Speer KP. The cosmetic appearance of the biceps muscle after long-head tenotomy versus tenodesis. *Arthroscopy* 2002;18:483-487.
- Verma NN, Drakos M, O'Brien SJ. The arthroscopic active compression test. *Arthroscopy* 2005;21:634.
- O'Brien SJ, Pagnani MJ, Fealy S, McGlynn SR, Wilson JB. The active compression test: A new and effective test for diagnosing labral tears and acromioclavicular joint abnormality. *Am J Sports Med* 1998;26:610-613.
- L'Insalata JC, Warren RF, Cohen SB, Altchek DW, Peterson MG. A self-administered questionnaire for assessment of symptoms and function of the shoulder. *J Bone Joint Surg Am* 1997;79:738-748.
- Richards RR, An KN, Bigliani LU. A self-administered questionnaire for the assessment of symptoms and function of the shoulder. *J Shoulder Elbow Surg* 1994;3:347-351.
- Laurencin CT, Deutsch A, O'Brien SJ, Altchek DW. The superolateral portal for arthroscopy of the shoulder. *Arthroscopy* 1994;10:255-258.
- Eakin CL, Faber KJ, Hawkins RJ, Hovis WD. Biceps tendon disorders in athletes. *J Am Acad Orthop Surg* 1999;7:300-310.
- Curtis AS, Snyder SJ. Evaluation and treatment of biceps tendon pathology. *Orthop Clin North Am* 1993;24:33-43.
- Kempf JF, Gleyze P, Bonomet F, Walch G, Mole D, Frank A, et al. A multicenter study of 210 rotator cuff tears treated by arthroscopic acromioplasty. *Arthroscopy* 1999;15:56-66.
- Neviaser TJ. The role of the biceps tendon in the impingement syndrome. *Orthop Clin North Am* 1987;18:383-386.
- Neviaser RJ, Neviaser TJ. Observations on impingement. *Clin Orthop Relat Res* 1990;254:60-63.
- Phillips BB, Canale ST, Sisk TD, Stralka SW, Wyatt KP. Ruptures of the proximal biceps tendon in middle-aged patients. *Orthop Rev* 1993;22:349-353.
- Carroll RE, Hamilton LR. Rupture of the biceps brachii. *J Bone Joint Surg Am* 1968;49:1016.
- Sturzenegger M, Beguin D, Grunig B, Jakob RP. Muscular strength after rupture of the long head of the biceps. *Arch Orthop Trauma Surg* 1986;105:18-23.
- Paulos LE, Mendez KT, Berg T. A novel approach to arthroscopic biceps tenodesis. *Orthop Tech Sports Med* 2007;15:27-34.